Orthodontic Mechano Treatment of Ectopic Eruption of the Permanent Mandibular Incisors of Iraqi Children (Early Mixed Dentition) A Longitudinal Clinical Study

Wisam Wahab Sahib Al-hamadi
College of Dental Medicine, University of Babylon, Hilla, Iraq.

Abstract

Fixed orthodontic appliances used to treat cases of bilateral distal ectopic eruption of the permanent mandibular central incisors. A total of 27 Iraqi children at average age of 7.5-years old selected for the study. 15 patients (9 females and 6 males) treated by extraction of the retained primary teeth and placement of fixed appliances for alignment and repositioning of the mandibular permanent incisors. while 7 patients (3 females and 4 males) treated by extraction of the corresponding retained primary tooth and later alignment of the mandibular incisors, and 5 patients (2 females and 3 males) treated by extraction of the relevant permanent lateral incisors and the corresponding retained primary teeth.

The result of present study showed significant difference between the first method of early mechanical orthodontic and another two methods of later mechanical orthodontic treatment regarding time consuming, esthetic and complexity factors. No significant differences clinically between gender groups and sides in the jaw. clinically the first method was easier and faster if compared with other methods of later orthodontic mechanical which may need a serial extraction, expansion or other orthodontic intervention that increase the complexity of cases treatment.

الخلاصة

تناولت هذه الدراسة السريرية الطويلة استخدام جهاز التقويم الثابت لمعالجة حالات متعددة من التطرف الجانبي لبزوغ القواطع الدائمية الأمامية السفلية.27 طفل عراقي أعمارهم ضمن السبع سنوات .تم تقسيمهم لإناث وذكور. 15 مريض 9 أنثى و6 ذكر عولجوا بقلع الأسنان اللبنية السفلية ذات العلاقة والاستخدام المبكر لجهاز التقويم الثابت لإعادة القواطع السفلية الأمامية لوضعها الصحيح.بينما عولج 7 منهم (3 إناث و4 ذكور) بقلع الأسنان اللبنية ذات العلاقة بالمشكلة فقط ومن ثم إجراء العلاج التقويمي فيما بعد.أما الخمسة الآخرين (2 إناث و3 ذكور) تم علاجهم بقلع الأسنان اللبنية السفلية ذات العلاقة بالإضافة للقواطع السفلية الجانبية الدائمية.

أظهرت النتائج السريرية أن هناك اختلاف كبير بين المجموعة الأولى التي عولجت بالجهاز التقويمي الثابت مبكرا والمجموعتين الأخريين اللتان تم التداخل التقويمي لهم فيما بعد, من حيث فترة العلاج وتعقيده والنتائج الجمالية لعملية التقويم.كما لم تسجل أية اختلافات سريرية بين الجنسين أو الجانب الأيمن والأيسر للفك السفلي .سريريا كانت الطريقة العلاجية بالاستخدام المبكر للجهاز التقويمي الثابت أسهل وأسرع وأفضل إذ قورنت بنتائج الطريقتين الأخريين قد تحتاج إلى متوالية قلع منتظمة أو توسيع الفك السفلي أو تداخلات علاجية إضافية.

Introduction

Dental eruption has been defined as the movement of a tooth from its original position of development to its functional position in the oral cavity [1]. In some cases, deviations from the normal pattern of eruption may occur leading to a change in the final position of the tooth, which is called ectopic eruption [2,16]. O'Meara stated that the most extreme case of ectopic eruption involves the eruption of the

tooth into a position normally occupied by another tooth *dental transposition* [3].

The prevalence of ectopic eruption of a permanent tooth associated with resorption of the adjacent primary tooth varies from 2% to 12% depending on the tooth involved [17]. O'Meara observed in a study of 315 cases of ectopic eruption involving central and lateral incisors and first permanent molars, a frequency of 12% to 52%, where 33% of the cases corresponded to ectopic eruption of the central incisor, without predilection to sex or side, the right side being more frequently involved, mainly in the cases of the central incisor [4].

The literature states some etiologic factors for ectopic eruption of lateral incisors: crowding, supernumerary teeth and idiopathic causes [2,15], as well as the premature loss of the primary canine and the prolonged retention of the corresponding primary teeth [5, 6]. O'Meara, who investigated ectopic eruption of central incisors, did not give an explanation for the etiology of such alteration [3]. Two types of treatments in cases of mandibular lateral incisor ectopic eruption have been proposed. The first involves extraction of the relevant permanent lateral incisor and the corresponding retained primary teeth. In cases of crowding, alignment of the remaining teeth is performed later [7,14]. The second type of treatment is extraction of the corresponding retained primary tooth and later alignment of the mandibular incisors. This strategy once performed in the initial stages of occlusion development, could provide enough space for the correct positioning of the permanent canines [4,16].

Aim of Study

The purpose of this study was to compare between different treatment methods in case of bilateral distal ectopic eruption of both mandibular permanent central incisors before the eruption of canines and first premolars, in order to minimize the collapse of the dental arch in the anterior region to avoid crowding and demand for anther orthodontic treatment.

Materials and Methods

Materials

Sets of dental exam (QD\England), ray-machine (atrophy \ France), dental extraction sets (QD\England), an orthodontic edgewise brackets ,arch wires(0.014 mm twist-flex ,0.014 mm round, 0.016 round) {orthomatrix \ USA}, check and lip retractors (orthomatrix - USA), lingual fixed retainer (Dentarium - Germany), and direct bonding system (Kerr\USA).

Samples criteria

Average of 7.5-year – old males and females patients at the early mixed dentition stage was diagnosed during routine clinical exam, with alternation in eruption pattern of the mandibular central incisors. these teeth erupted distally to the corresponding primary teeth, which were not normally exfoliated (fig. 1) and had no signs of physiologic resorption (fig. 2). The molars in Angle CI I position and mandibular primary canines in cross bite.

Excess space was present in the mandibular arch, and the primary incisors were slightly flared or proclined. The diagnosis was ectopic eruption of permanent mandibular incisors. no crowding or supernumerary teeth founded in all samples.

Methods

Diagnosis done for all cases selected, The treatment objectives

consisted of extraction of retained primary teeth first, followed by alignment of the permanent incisors.

Fifteen days after extraction of primary central incisors, direct bonding procedure done to edgewise brackets were placed on incisors and primary canines, but not on the permanent lateral incisors, which was still erupting or partially erupted. twist-flex arch wire (0.014 mm - orthomatrix) was used for the leveling and alignment of the teeth(fig.3). After 2 weeks, it was replaced by a round (0.014mm-orthomatrix) stainless steel arch wire to improve alignment. After a month, (0.016mm-orthomatrix)arch wire was made and elastic chain were used to close the Diastema (fig.4). The treatment time and retention period required for each treatment method were as listed at table (1) and (fig. 7 and 8).

Result and Discussion

Two months after beginning treatment, a normal inclination of the incisors and correction of the cross bite of the primary canines were obtained (fig. 5 and 6). After the complete eruption of permanent lateral incisors, the fixed appliance is completely removed and replaced by lingual fixed retainer. until eruption of the permanent canines.

The permanent mandibular incisors normally develop lingually to the corresponding primary teeth [8,12]. Their lingual eruption usually lead to non exfoliation of the primary teeth, a normal situation not requiring any intervention, since their anterior migration will occur by the action of the tongue musculature, concurring with the growth and development of the mandibular anterior segment(9,14). in this study, this was not the pattern of eruption found, as the incisors showed a distal direction of eruption in relation to their corresponding primary teeth. This lead to the diagnosis of ectopic eruption, which was in agreement with study by Schaad and Thompson [10].

The etiological factors for this eruption alternation, specifically of lateral incisors, have been cited by some authors as crowding, supernumerary teeth, idiopathic causes [2,12], premature loss of the primary canine [5], and prolonged retention of the corresponding primary teeth [6,15].

In the current cases, ectopic eruption of the permanent central incisors was diagnosed, but crowding and presence of supernumerary teeth were not present, although slight spacing was found in the affected arch. This may be considered an important factors in the etiology since in the presence of excess space, teeth may lose their eruption guidance and could deviate from the roots of the primary teeth. Tylor and Hamilton's study involving 16 cases of ectopic eruption of the lateral incisor also observed that in more than half of their sample, the affected dental arch had sufficient space to accommodate all teeth [2,15].

Sweet suggests that one of the factors responsible for the alternation in the eruption position of the lateral incisors could be the premature loss of the primary canine, leading to an eruption pattern with a distal orientation [5]. Tylor and Hamilton's disagree with this suggestion, because in their sample the canine and the lateral primary incisor were rarely absent. In the current cases there was not premature exfoliation of any primary tooth, probably due to the irregular axial inclination of the teeth on the anterior segment that contributed to the positive discrepancy, enabling the eruption of the central incisors [2,15].

The prolonged retention of the corresponding primary teeth was a condition present in the current cases of patients. Rose pointed to this factors

as the possible cause of ectopic eruption, but Tylor and Hamilton's consider it to be the result of the ectopic eruption of its successor [6,11]. Bradley and bell concluded that it was not clear whether the prolonged retention of the primary teeth is the result or the cause of the alternation of eruption pattern of the permanent successors. They state that the lack of a correct intra osseous positioning of the teeth would not cause adequate pressure on the primary root to stimulate resorption. Thus delayed exfoliation would be a secondary characteristic [4,13].

The treatment for this cases of bilateral ectopic eruption of the mandibular central incisors was the extraction of the primary teeth with prolonged retention followed by realignment and leveling of the mandibular anterior segment as showing in (fig. 8). This strategy is in agreement with Bradley and Bell. The recommended correction in the initial stages of the malocclusion, as it provides a better chance for the correct positioning of the permanent canines and first premolars, and apart from favoring a good prognosis, also makes faster and easier [4,13], if compared with other methods of later mechano-therapy that may need for serial extraction or expansion…etc, that means increase complexity of cases. Table (1) and (fig. 7) demonstrate the differences in orthodontic treatment time of three methods.

Conclusions

a- Later mechano therapy makes the demand for serial extraction or expansion or any other orthodontic intervention therapy occurring.

b- In the presence of ectopic eruption of the mandibular central incisors, diagnosis and intervention in the early mixed dentition is recommended.

c- Orthodontic treatment performed before the eruption of the permanent canines may reduce the time and complexity of the procedure, favoring an adequate of the dentition

References

1- Massler M,Schour I. Studdies in tooth development:Theories of eruption.Am J Orthod 1941; 27: 552-556.

2- Taylor GS, Hamilton MC. Etopic eruption of lower lateral incisors.ASD J Dent Child 1971; 38: 282-284.

3- Fleming PS, Johal A, DiBiase AT. Managing malocclusion in the mixed dentition: six keys to success. Part 1. Dent Update. 2008 Nov; 35(9): 607-10.

4- O′Meara WF. Ectopic eruption pattern in selected permanent teeth.J Dent Res 1962; 41: 607-616.

5- Schopf P. Indication for and frequency of early orthodontic therapy or interceptive measures. J Orofac Orthop. 2003 May; 64 (3): 186-200.

6- Bradley EJ, Bell RA. Eruptive malpositioning of the mandibular permanent lateral incisors: Three case reports.Pediatr Dent 1990; 12: 380-387.

7- Keski-Nisula K, Hernesniemi R, Heiskanen M, Keski-Nisula L, Varrela J. Orthodontic intervention in the early mixed dentition: a prospective, controlled study on the effects of the eruption guidance appliance. Am J Orthod Dentofacial Orthop. 2008 Feb;133 (2): 254-60.

8- Bennett N. The science and practice of dental surjery.Oxford: Oxford university Press,1990.Apud in: Deery E.The relashionship of crowding of crowding to the eruptive position of the lower permanent incisors.Br J Orthod 1993; 20:333-337.

9- Gellin ME, Haley JV. Managing cases of over-retention of mandibular primary incisors where their permanent successors erupt lingually.

AsDC J Dent Child 1982;49:118-122.
10- Schaad TD, Thompson HE.Extreme ectopic eruption of the lower permanent lateral incisors. Am J Orthod 1974; 66: 280-286.
10- Schaad TD, Thompson HE.Extreme ectopic eruption of the lower permanent lateral incisors. Am J Orthod 1974; 66: 280-286.
11- Russell KA. Orthodontic treatment in the mixed dentition. J Can Dent Assoc. 1996 May; 62 (5): 418-21.
12- Sweet CA.Ectopic eruption of permanent teeth. J Am Dent Assoc 1939; 26: 574-579.
13- Steegmayer G, Komposch G. Early orthodontic treatment of the deciduous dentition. The therapeutic potentials and indications. Fortschr Kieferorthop. 1993 Aug; 54 (4): 172-8.
14- Rose JS. Atypical paths of eruption:Some cases and effects.Dent Pract 1958;9:69-76.
15- Shapira Y, Kuftinec MM. The ectopically erupted mandibular lateral incisor. Am J Orthod 1982; 82: 426-429.
16- Boute S, Kleutghen J. Early orthodontic treatment. Rev Belge Med Dent. 1989; 44 (3): 39-53.
17- Stahl F, Grabowski R. Orthodontic findings in the deciduous and early mixed dentition--inferences for a preventive strategy. J Orofac Orthop. 2003 Nov; 64 (6): 401-16.

Figure1 Showing the retained mandibular deciduous teeth before treatment.

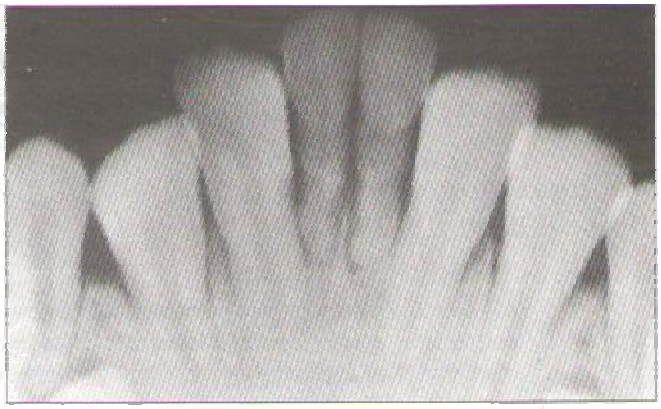

Figure 2 Periapical radiography showing ectopic eruption of mandibular incisors and retained deciduous teeth

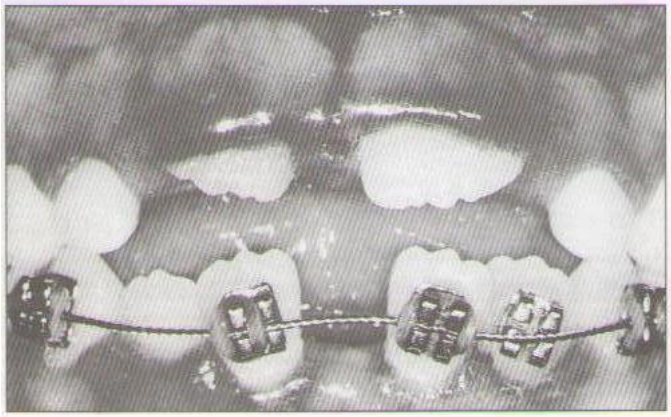

Figure 3 Direct bonding of fixed appliance after extraction of retained deciduous teeth. With twist-flex arch wire.

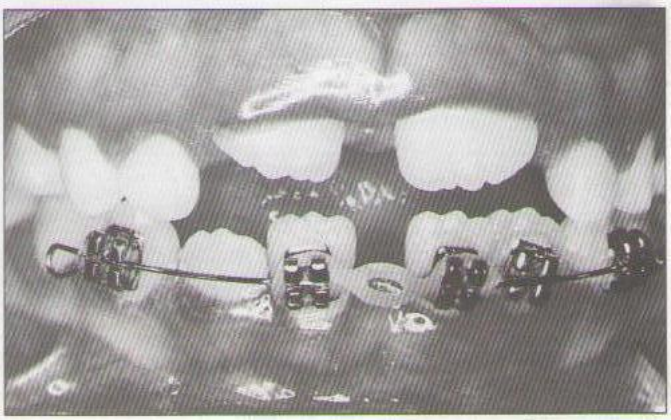

Figure 4 Placement of power chain between mandibular incisors to close the diastema. With arch wire 0.16 mm.

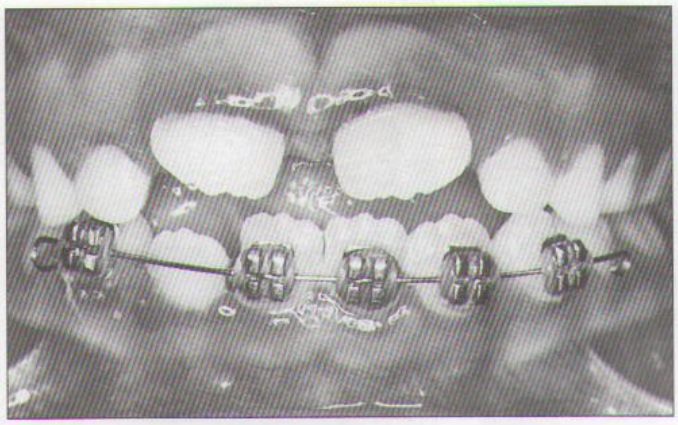

Figure 5 Final repositioning of mandibular incisors excluding the permanent lateral incisor (Still Erupting). With arch wire 0.18 mm.

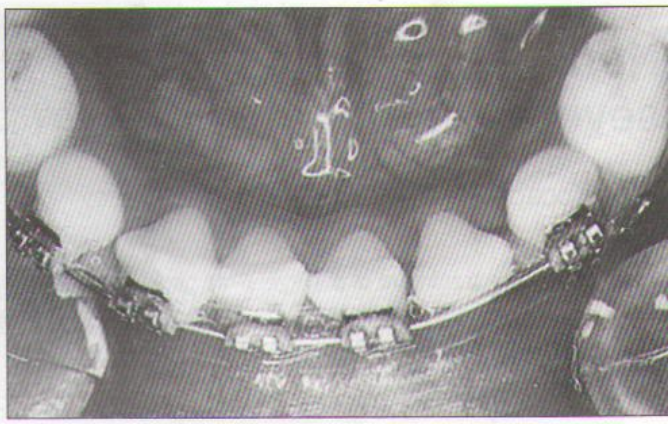

Figure 6 Final repositioning and case is ready for retention procedure.

Table 1 Demonstrate the time of treatment and retention period (months) for each method.

Treatment Method	Treatment Time (Monthes)	Retention Time (Monthes)
Early Fixed Orthodontic Appliance with primary teeth extraction	**6**	**55**
Later Fixed Orthodontic Appliance with primary teeth extraction	**48**	**6**
Later Orthodontic Appliance with permanent and primary teeth extraction	**13**	**6**

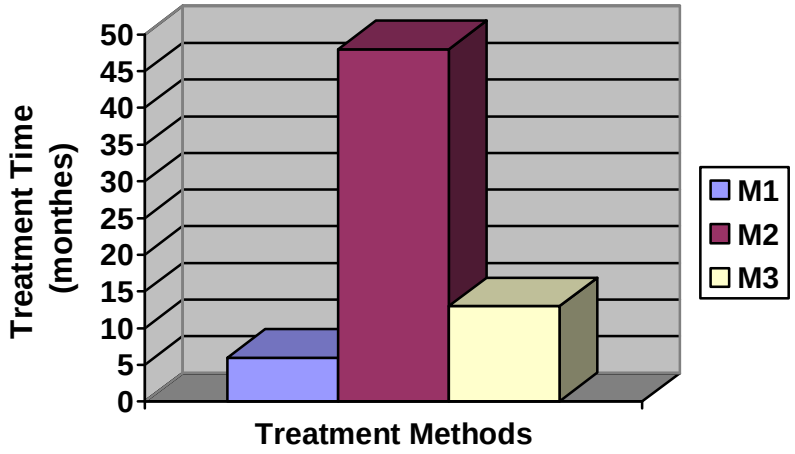

M1 = Early Fixed Orthodontic Appliance with primary teeth extraction
M2 = Later Fixed Orthodontic Appliance with primary teeth extraction
M3 = Later Orthodontic Appliance with permanent and primary teeth extraction

Figure 7 A histogram showing the time required for each treatment method.

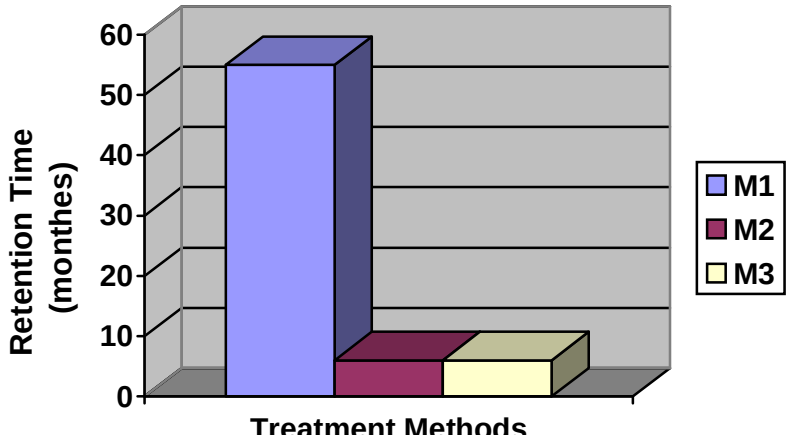

M1 = Early Fixed Orthodontic Appliance with primary teeth extraction
M2 = Later Fixed Orthodontic Appliance with primary teeth extraction
M3 = Later Orthodontic Appliance with permanent and primary teeth extraction

Figure 8 A histogram showing the retention period required for each treatment method.