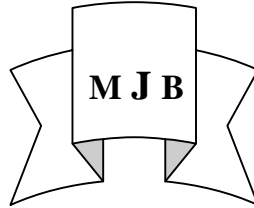


The Value of Scrotal Ultrasound in Evaluation of Adult Hydrocele

Mohamad Noori Almusawi
College of Medicine- Kufa University,IRAQ.



Abstract

Retrospective study to evaluate the role of scrotal ultrasound in assessment of patients with clinically diagnosed hydrocele was conducted.

Hundred patients with provisional diagnosis of hydrocele checked by scrotal ultrasound 7.5 mega Hertz linear probe, scrotal ultrasound showed that 2 patients had testicular tumor, 3 patients had epididymal cyst and 2 patients had communicating hydrocele. Scrotal ultrasound finding was confirmed by surgical exploration and histopathological examination if required.

Scrotal ultrasound in our study proved to have 100% sensitivity, specificity and accuracy in evaluation of patients with hydrocele.

We conclude that scrotal ultrasound is very essential in checking patients with hydrocele to choose the appropriate surgical approach .

الخلاصة

دراسة رجعية الى آخر 100 مريض بالتتابع مصاب بقليلة مائية حسب التشخيص الاولي عولجوا في شعبة الجراحة البولية - كلية الطب - جامعة الكوفة جراحياً، تراوحت اعمارهم بين (16 - 55) سنة، كانت القليلة لكلا الخصيتين في تسعة مرضى وفي الجهة اليسرى لتسعة واربعون مريضاً وفي الجهة اليمنى لأثنان واربعون مريضاً. فحوص سونار الخصية بينت وجود ورم خصية في احد المرضى مختفي في قيلة مائية ثانوية ووجود ورم خصية شغل كل كيس الصفن في المريض الثاني، فحوص السونار غيرت التشخيص الاولي الى كيس منوي في ثلاثة مرضى وبينت وجود فتق مغبني مصاحب للقليلة المائية في اثنين آخرين. تم التاكيد من نتائج فحوص السونار بالتداخل الجراحي والفحص النسيجي ان تطلب. فحوص السونار للقليلة المائية كانت ذو حساسية وخصوصية ودقة مقدارها 100% . ان اجراء فحص سونار الخصية للمرضى ذوي القيلة المائية قبل اجراء العملية الجراحية هو شيء اساسي لمعرفة التشخيص النهائي (قيلة اولية، ورم خصية، كيس منوي، فتق مصاحب) من اجل اختيار الاسلوب الجراحي الذي يجب ان يتبع في المعالجة.

Introduction

Hydrocele is excessive collection of serous fluid in some parts of the processes vaginalis usually the tunica which is either caused by excessive fluid production as in inflammatory process or by defective fluid absorption as in idiopathic hydrocele, or by interference with lymphatic drainage which may follow scrotal surgery as varicocele, or due to patent processus vaginalis and fluid

passage from and to peritoneal cavity. [1,2]

Hydrocele either congenital by patent (communicating) processus vaginalis known as infantile hydrocele, but when processus vaginalis was incompletely closed leaving encysted hydrocele of spermatic cord, or hydrocele is acquired which either primary (idiopathic) or secondary to inflammation (chronic non specific epididymo orchitis

or TB epididymitis), trauma, malignancy, heart failure and filariasis or secondary to surgical intervention[3].

hydrocele is painless scrotal swelling, by clinical examination we can get above it and it is cystic in consistency, it may be tense in which the testicle can not be palpated or lax one.

The patient has social embarrassment of large scrotum and may have urinary voiding symptoms as dysuria, frequency when hydrocele secondary to ascending infection. [4]

Congenital hydrocele (communicating one) should be managed by inguinal approach to close its communication with peritoneal cavity otherwise it recure and it usually presents in pediatric age but may persist or present in adolescence or adult life and its patent processes vaginals may allow omentum to pass in to scrotum.

Idiopathic hydrocele, hydrocele secondary to inflammation or trauma are managed by scrotal approach and the tunica is excised if it is thick one or it is bunched up by series of catgut sutures (Lord's operation), or the tunica is everted and placement of the testicle in pouch prepared by blunt dissection in the fascial plans of the scrotum (Jaboulay's operation).[1,5]

Secondary hydrocele to testicular tumor must be managed by inguinal approach to do radical orchidectomy.

Scrotal approach is not recommended for hydrocele secondary to testicular tumors as it often followed by opening new lymphatic channels for metastasis by scrotal lymphatic to superficial inguinal lymph nodes.[6]

Secondary hydrocele caused by heart failure is managed medically by anti failure measures.[7]

Evaluation of hydrocele pre operatively is always needed for proper surgical approach and this aim is simplified by scrotal ultrasound.

Patients and Methods

Retrospective study in which the clinical records of the last 100 consecutive patients with hydrocele who were managed by one hospital urological team surgically were evaluated.

Their age was ranged between 16 – 55 years (9 had bilateral hydrocele, 49 had left hydrocele and 42 had right hydrocele) their scrotal mass was painless, can get above it and the testicle can not be palpated. Every scrotum was checked by ultrasound 7.5 mega Hertz linear probe to evaluate testicular out line, echogenicity and the testicle whether homogenous or not , epididymal and spermatic cord structure were also evaluated. Ultrasound finding was compared with the result of surgical exploration which was done by scrotal or inguinal approach .

Results

Scrotal ultrasound showed testicular tumors in 2 patients, 1 patient had testicular mass which was surrounded by secondary hydrocele while other patient scrotal ultrasound showed testicular mass occupying all scrotum without hydrocele. Exploration of both patients by inguinal approach and radical orchidectomy was done. Histopathological check showed teratocarcinoma in the first while in the second patient it showed seminoma.

In 3 patients ultrasound checking did not show hydrocele fluid but the mass was epididymal cyst which was documented by scrotal exploration.

In 2 patients scrotal ultrasound showed herniated omental mass floating in the hydrocele fluid, the approach for those 2 patients was inguinal for the scrotum in which hernial repair and jampoly's operation was done.

In the remaining patients ultrasound finding showed hydrocele fluid clearly with no additional abnormal finding and the diagnosis was documented

Table 1 Site of hydrocele

Left hydrocele	49
Right hydrocele	42
Bilateral hydrocele	9

Table 2 Results of scrotal ultrasound

Testicular tumors	2
Communicating hydrocele	2
Epididymal cyst	3
Pure hydrocele	84 + 9 bilateral

Discussion

Knowing the type of hydrocele preoperatively is vital for proper patient management. Communicating hydroceles are congenital in origin, however it is not uncommon for a communicating hydrocele to manifest clinically for the first time in adolescent. Most of these late onset communicating hydroceles are found to be associated with omental hernia in which descent of a plug of omentum through the internal inguinal ring has caused a sudden increase in the amount of fluid in the scrotum. All communicating hydroceles should be explored through an inguinal incision, scrotal approach always has residual communication and recurrence.[8]

Testicular tumor may present with diffuse firm and non tender mass as that for hydrocele, transillumination of the scrotum and scrotal ultrasound can help to distinguish between these entities, but hydrocele may accompany 5-10 % of testicular tumor and help to camouflage it so that the testicles can not be adequately examined and scrotal ultrasound is mandatory. Aspiration of the hydrocele should be avoided because positive cytological results have been reported in hydrocele associated with testicular tumors. Preoperative diagnosis changes surgical approach when hydrocele is secondary to testicular tumor as radical orchidectomy is needed. Missed diagnosis with scrotal approach for testicle with

malignancy open inguinal lymphatic channels.[9]

Epididymal cyst (spermatocele) is easily diagnosed clinically by palpation. It is smooth freely movable cystic lesion separated from testicle and just above and posterior to it but some time it is so large and tense pushing the testicle to inferior pole of the scrotum and clinically can not be differentiated from hydrocele as both conditions are transilluminating lesions. Scrotal ultrasound differentiates these by fluid surrounding the testicle in hydrocele or cyst compressing the testicle downward in epididymal cyst.[10]

Of these (100) patients scrotal ultrasound showed (4) true negative results (1 tumor and 3 epididymal cysts) and (96) true positive results and accordingly scrotal ultrasound sensitivity, specificity and accuracy in evaluation of patients with clinical diagnosis of hydrocele were 100%.

Scrotal ultrasound for adult hydrocele become standard tool in accurate evaluation. High resolution scrotal ultrasound should be performed in all men with hydrocele [1].

Ultrasound should be done if the diagnosis of hydrocele in young men without apparent cause. Careful evaluation of the testicle and epididymis should be done in order to rule out cancer or infection. This is best done by scrotal ultrasound. [9]

In conclusion we find that every scrotum with clinical diagnosis of hydrocele must be checked by ultrasound to:

1- Confirm the diagnosis of hydrocele which can mimic globular testicular

tumor and to exclude testicular tumors which may be hidden cause for hydrocele.

2- Exclude associated inguinal hernia (communicating hydrocele).

3- Pre operatively differentiate epididymal cysts from hydrocele.

References

- 1- Russell R, Williams N, Buistrod C. Baily and love's, Short Practice Of Surgery. Twenty forth Edition. London. Arnold a member of Holder Headline group, 2004, 1407.
- 2- Galal S, Barsom M, Mohsen A, Fawzi T, Abdel Halim S. Kasr EL Aini, Introduction To Surgery. Third Ed.. Egypt. AL Ahram press Kalyonb, 2004, 625.
- 3- Blandy J. Lecture Notes On Urology. Second Edition. Oxford. Black well scientific Publications, 1979, 240.
- 4- Norman L, Browse K. An Introduction To The Symptoms and Signs Of Surgical Diseases. Third Ed. London. Arnold amember of holder headline group, 1997,355.
- 5- Lawrence W. Current Surgical Diagnosis And Treatment. Ninth Ed. Labanon. libairie deliban BN O5M 500018, 1991, 1199.
- 6- Mundy AR. Essential Urology. Churchill livingstone.Edinhugh.1989; 314.
- 7- Robin CN, Williamson, Bruce P. SCOTT, An Aid To Clinical Surgery. Sixth Ed. Singapura. Longman Singapore publishers (pte) Ltd, 1998, 350.
- 8- Walsh P, Petik A, Vaugham D. et al. Campbell's Urology. Eighth Ed. Philadelphia. The curtis center, 2002, 1579.
- 9- Tanagho EA. Smith's General Urology. Sixteenth Edition. USA. Lange Medical Books, 2004, 389.
- 10- Tanagho EA. Smith's General Urology. Thirteenth Edition. Lebanon. Librairie Du Liban, 1992, 620